

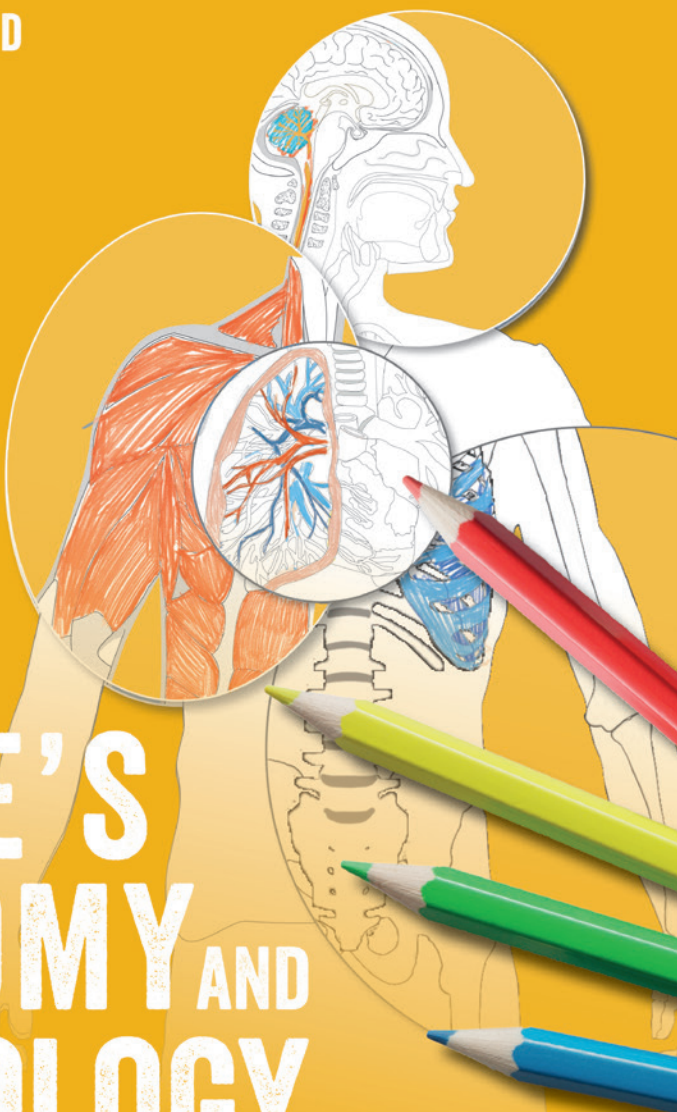
'Fun and calming ... what a great way to learn!'

NEAL COOK

ANDREA SHEPHERD

3rd
Edition

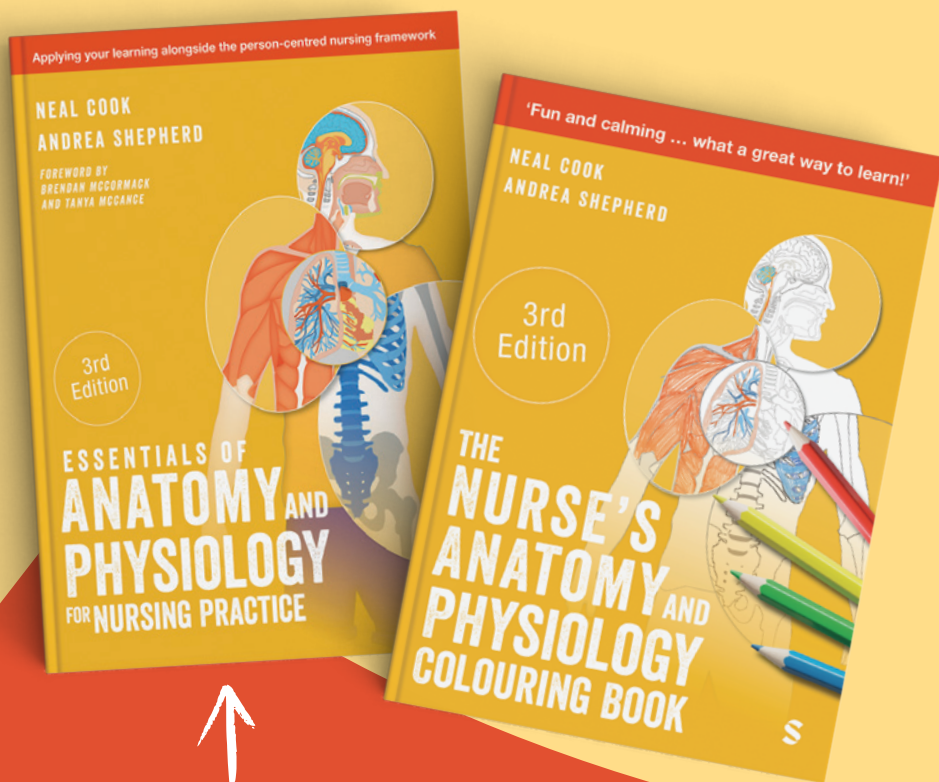
THE
NURSE'S
ANATOMY AND
PHYSIOLOGY
COLOURING BOOK



S

A COMPREHENSIVE STUDY PACKAGE

Designed to build a strong foundation in anatomy and physiology while ensuring stress-free revision.



Pair with the bestselling *Essentials of Anatomy and Physiology for Nursing Practice* for the best results.



also available
on Amazon

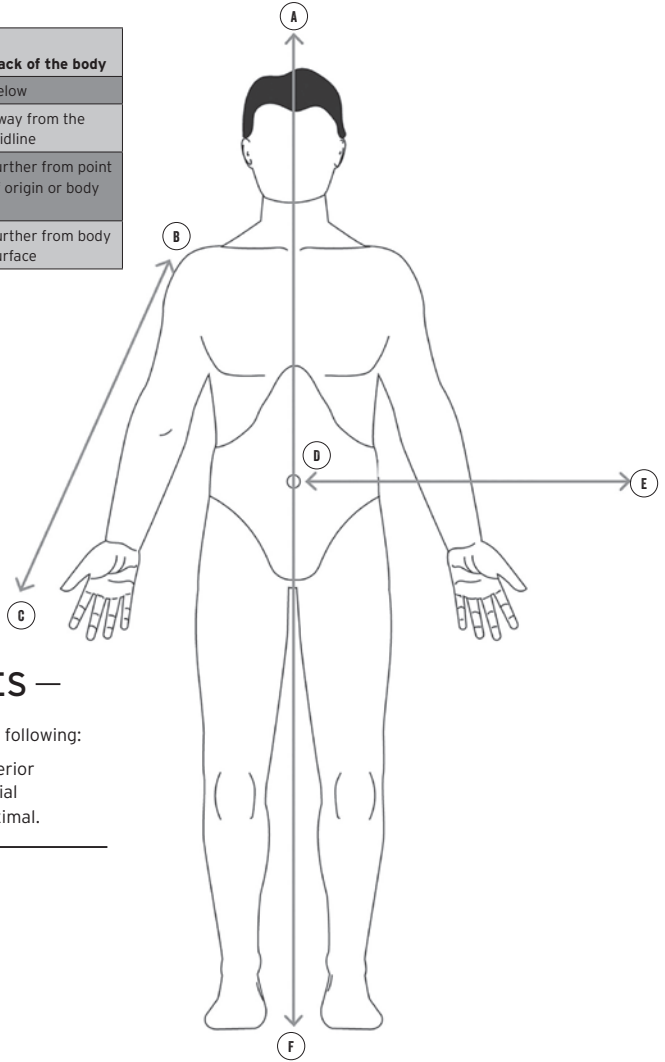
ISBN: 9781036212001

ANATOMICAL DIRECTIONS

INTRODUCTION

The table below shows the terms used to indicate the relative positions of the organs and parts of the body.

Ventral/ anterior	Front of the body	Dorsal/ posterior	Back of the body
Superior	Above	Inferior	Below
Medial	Towards the midline	Lateral	Away from the midline
Proximal	Closer to point of origin or body	Distal	Further from point of origin or body
Superficial	Closer to body surface	Deep	Further from body surface



— COLOURING NOTES —

Using the arrows, correctly label the following:

- Inferior
- Lateral
- Distal
- Superior
- Medial
- Proximal.

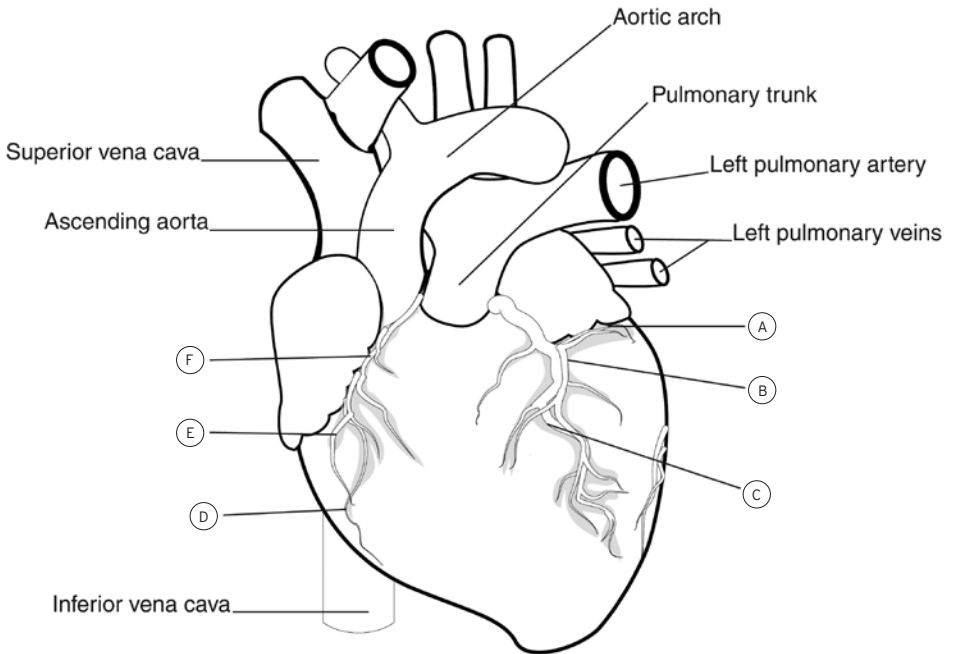
CORONARY CIRCULATION

INTRODUCTION

The coronary circulation supplies blood to the heart itself. Just above the aortic valve lies the opening to the right and left coronary arteries, which supply blood to the heart.

COLOURING NOTES

- Identify and label the following:
 - Anterior cardiac veins
 - Anterior interventricular artery
 - Circumflex artery
 - Great cardiac vein
 - Marginal artery
 - Right coronary artery.
- Colour all arteries red and veins blue.
- Colour the remainder of the heart pink.



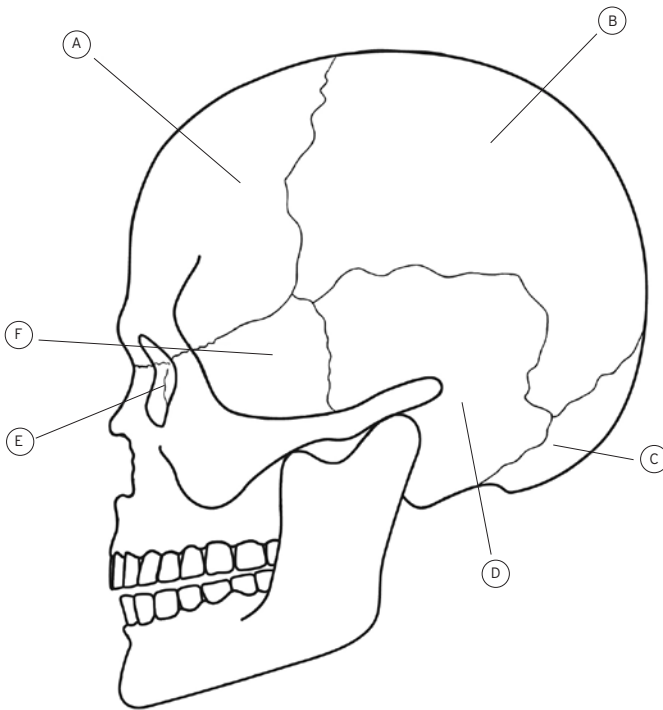
THE CRANIAL BONES

INTRODUCTION

These eight bones form the cranial cavity which encloses and protects the delicate tissue of the brain. The eight cranial bones are: the frontal bone, two parietal bones, two temporal bones, the occipital bone, the sphenoid bone and the ethmoid bone.

COLOURING NOTES

- | | |
|---|--|
| <input type="checkbox"/> Identify and label the ethmoid bone. Colour it brown. | <input type="checkbox"/> Identify and label the sphenoid bone. Colour it blue. |
| <input type="checkbox"/> Identify and label the frontal bone. Colour it green. | <input type="checkbox"/> Identify and label the temporal bone. Colour it orange. |
| <input type="checkbox"/> Identify and label the occipital bone. Colour it yellow. | <input type="checkbox"/> Identify the mandible. Colour it grey. |
| <input type="checkbox"/> Identify and label the parietal bone. Colour it purple. | |
-



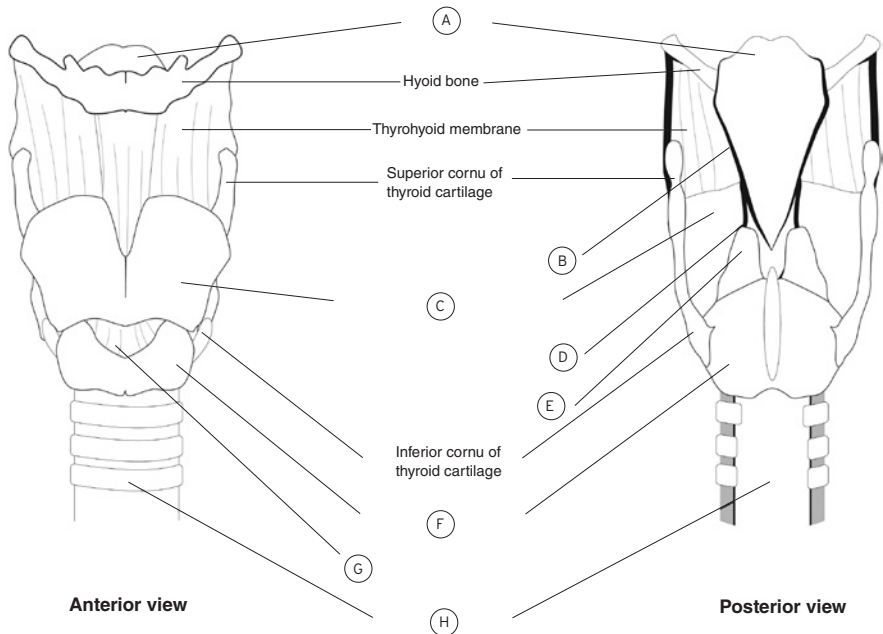
ANATOMY OF THE LARYNX

INTRODUCTION

The larynx (voice box) connects the laryngopharynx and trachea; it is positioned midline in the neck, anterior to the oesophagus and from the fourth to sixth cervical vertebrae (C4–C6). The wall of the larynx is comprised of nine pieces of cartilage with three occurring singularly (thyroid, cricoid and epiglottis) and the other six occurring in pairs (arytenoid, corniculate and cuneiform). The cartilages are connected to one another by muscles and ligaments; extrinsic muscles connect the cartilages to other structures in the throat, and intrinsic muscles connect the cartilages to each other.

COLOURING NOTES

- Colour the hyoid bone grey.
- Colour the thyrohyoid membrane red.
- Identify and label the arytenoid cartilage. Colour it yellow.
- Identify and label the corniculate cartilage. Colour it orange.
- Identify and label the cricoid cartilage. Colour it brown.
- Identify and label the cricothyroid ligament. Colour it black.
- Identify and label the cuneiform cartilage. Colour it blue.
- Identify and label the epiglottis. Colour it green.
- Identify and label the thyroid cartilage. Colour it purple.
- Label the trachea. Identify the c-shaped rings of hyaline cartilage around the trachea. Colour them pink.



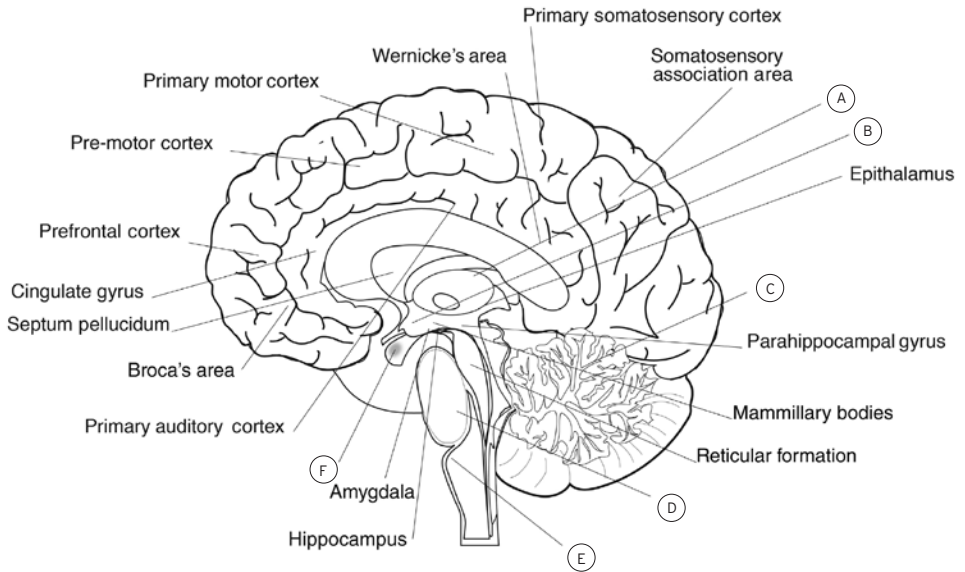
STRUCTURE OF THE BRAIN

INTRODUCTION

The brain is divided into three main structures: the forebrain, the midbrain and the hindbrain. Each of these structures work together to maintain homeostasis. Different parts of the brain have different roles.

COLOURING NOTES

- Identify and label the thalamus and hypothalamus. Colour the thalamus orange.
- Identify and label the cerebellum. Colour it purple.
- Identify and label the pituitary gland. Colour it yellow.
- Identify and label the pons and medulla oblongata. Colour these blue.
- Colour the forebrain green.



COMPONENTS OF THE EYE

INTRODUCTION

The eye is a sphere about 2.5 cm in diameter and five-sixths of it is concealed within the orbit, with one-sixth visible. It has three principal components:

1. The three-layered wall.
2. The optical components that focus light and regulate its entry to the eye.
3. Neurological components that convert light to electrochemical energy to generate images.

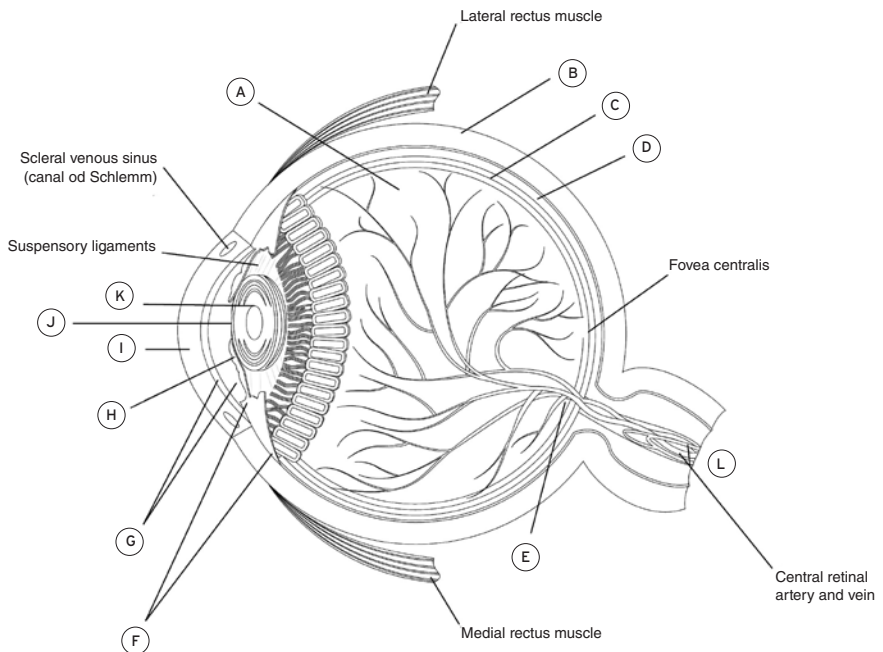
COLOURING NOTES

Identify and label the following:

- Posterior cavity
- Anterior cavity
- Ciliary body
- Optic disc
- Optic nerve
- Sclera
- Retina
- Choroid
- Cornea
- Lens

- Pupil
- Iris.

- Colour the posterior cavity light green.
- Colour the anterior cavity dark blue.
- Colour the ciliary body pink.
- Colour the optic nerve red.
- Colour the sclera yellow.
- Colour the retina orange.
- Colour the choroid dark green.
- Colour the cornea light blue.
- Colour the iris purple.



PARTS OF THE STOMACH

INTRODUCTION

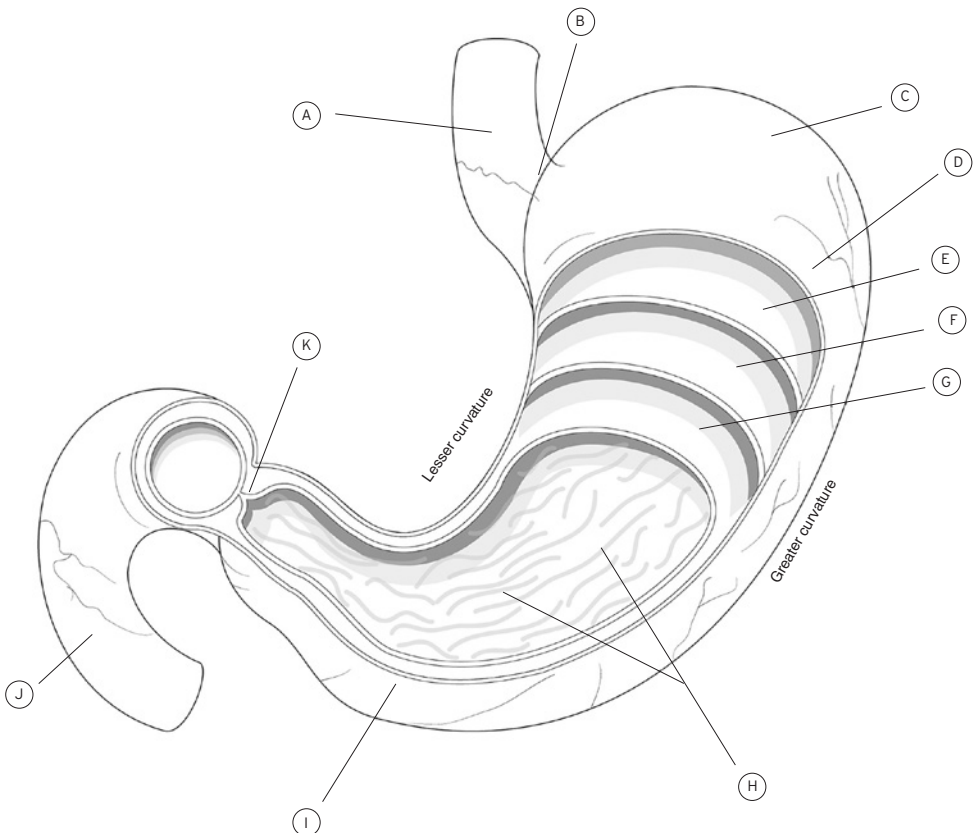
The stomach is a bean-shaped sac designed to house food for digestion. As the food bolus moves into the stomach, the pyloric sphincter (at the exit from the stomach) closes to retain the food for digestion. Chemical and mechanical digestion both occur in the stomach.

COLOURING NOTES

□ Identify and label the following:

- Body
- Cardiac sphincter
- Fundus
- Pyloric antrum
- Pyloric sphincter
- Rugae.

- Identify and label the circular muscle. Colour it yellow.
- Identify and label the duodenum. Colour it purple.
- Identify and label the longitudinal muscle. Colour it orange.
- Identify and label the oblique muscle. Colour it red.
- Identify and label the oesophagus. Colour it blue.
- Identify the epithelial layer. Colour it green.
- Identify the serosa layer. Colour it pink.



GROSS ANATOMY OF THE LIVER

INTRODUCTION

The liver is the largest glandular organ in the body and normally weighs between 1.4 and 1.6kg in the healthy adult. It is in the right upper quadrant of the abdomen (right hypochondrium) under the diaphragm, behind and protected by the lower ribs. Gross anatomy divides the liver into four lobes based on surface features. When you look at the liver from the front (anterior surface) you will see the falciform ligament; this divides the liver into the left lobe and the right lobe (larger of the two). If the liver is flipped over to look at it from behind (posterior surface) you will see two more lobes between the right and left lobes – these are the caudate lobe (superior of the two) and the quadrate lobe.

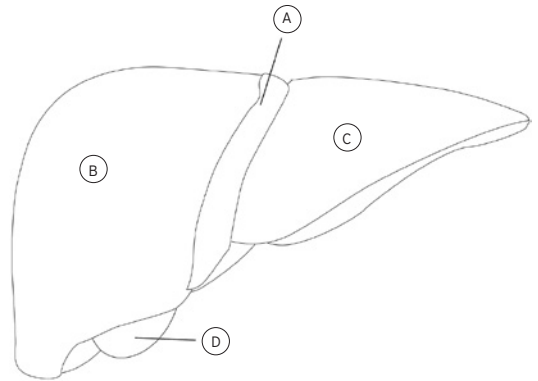
COLOURING NOTES

Anterior view:

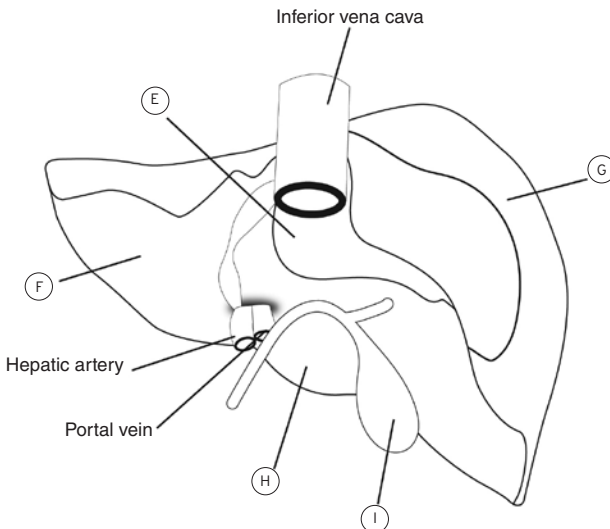
- Identify and label the falciform ligament. Colour it yellow.
- Identify and label the gall bladder. Colour it green.
- Identify and label the right and left lobes. Colour them red.

Posterior view:

- Identify and label the gall bladder. Colour it green.
- Identify and label the right, left, caudate and quadrate lobes. Colour the right red, the left orange, the caudate pink and the quadrate brown.



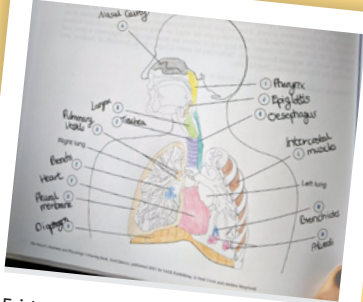Anterior view



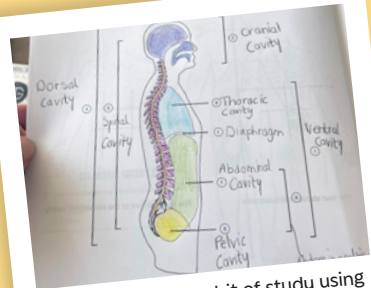
Posterior view

SHARE WITH US

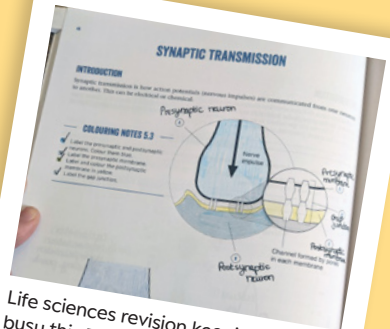
Join thousands of nursing students who have transformed their anatomy and physiology learning using this creative and relaxing approach.



Friday afternoon learning! Respiratory system 🦋 #NursingInColour



#NursingInColour a bit of study using the anatomy and physiology colouring book before I try the practice test for Life Sciences 😊



Life sciences revision keeping me busy this Easter! Currently on the Nervous System! 🧠
















I'm not so good at staying in the lines, but it's still a great way to study!



Share your completed artwork using **#NursingInColour** on X and Instagram for a chance to win an exciting surprise prize!

THE ESSENTIALS OF NURSING COLLECTION



Learn more

Lecturers can order inspection copies of these books at sagepub.co.uk/nursing-essentials

